

Glenohumeral Range of Motion Deficits and Posterior Shoulder Tightness in Throwers With Pathologic Internal Impingement

Joseph B. Myers,^{*†‡} PhD, ATC, Kevin G. Laudner,[§] PhD, ATC, Maria R. Pasquale,[†] MS, James P. Bradley,[‡] MD, and Scott M. Lephart,^{†‡} PhD, ATC

From the [†]Neuromuscular Research Laboratory, Department of Sports Medicine and Nutrition, School of Health and Rehabilitation Sciences and the [‡]Department of Orthopaedic Surgery, University of Pittsburgh, Pittsburgh, Pennsylvania, and the [§]Biomechanics Laboratory, School of Kinesiology and Recreation, Illinois State University, Normal, Illinois

Background: Alterations in glenohumeral range of motion, including increased posterior shoulder tightness and glenohumeral internal rotation deficit that exceeds the accompanying external rotation gain, are suggested contributors to throwing-related shoulder injuries such as pathologic internal impingement. Yet these contributors have not been identified in throwers with internal impingement.

Hypothesis: Throwers with pathologic internal impingement will exhibit significantly increased posterior shoulder tightness and glenohumeral internal rotation deficit without significantly increased external rotation gain.

Study Design: Case control study; Level of evidence, 3.

Methods: Eleven throwing athletes with pathologic internal impingement diagnosed using both clinical examination and a magnetic resonance arthrogram were demographically matched with 11 control throwers who had no history of upper extremity injury. Passive glenohumeral internal and external rotation were measured bilaterally with standard goniometry at 90° of humeral abduction and elbow flexion. Bilateral differences in glenohumeral range of motion were used to calculate glenohumeral internal rotation deficit and external rotation gain. Posterior shoulder tightness was quantified as the bilateral difference in passive shoulder horizontal adduction with the scapula retracted and the shoulder at 90° of elevation. Comparisons were made between groups with dependent *t* tests ($P < .05$).

Results: The throwing athletes with internal impingement demonstrated significantly greater glenohumeral internal rotation deficit ($P = .03$) and posterior shoulder tightness ($P = .03$) compared with the control subjects. No significant differences were observed in external rotation gain between groups ($P = .16$).

Clinical Relevance: These findings could indicate that a tightening of the posterior elements of the shoulder (capsule, rotator cuff) may contribute to impingement. The results suggest that management should include stretching to restore flexibility to the posterior shoulder.

Keywords: throwing; glenohumeral internal rotation deficit (GIRD); impingement

Physical examination of overhead-throwing athletes consistently demonstrates adaptive glenohumeral internal and external rotation range of motion of the dominant

shoulder when compared with the nondominant limb. It can be concluded based on the results of several studies that throwers demonstrate significantly increased glenohumeral external rotation (external rotation gain) and significantly decreased glenohumeral internal rotation (glenohumeral internal rotation deficit [GIRD]) in the throwing arm.^{1,2,5,9,32,34}

The reason for this altered range of motion is not clear, but it is believed to be a natural adaptation that develops in all throwers. Theories related to external rotation gain and GIRD include the presence of subtle microtrauma to the static and dynamic restraints of the glenohumeral joint from repetitive overhead throwing,^{1,10,33} contracture of the posteroinferior joint capsule,^{3,37} and osseous adaptation of

*Address correspondence to Joseph B. Myers, PhD, ATC, Neuromuscular Research Laboratory, UPMC Center for Sports Medicine, 3200 South Water Street, Pittsburgh, PA 15203 (e-mail: myersjb@upmc.edu).

Presented at the interim meeting of the AOSSM, Washington, DC, February 2005.

No potential conflict of interest declared.

the humerus.^{5,29,32} Despite the apparent alterations in the amount of rotation, the amount of total humeral rotation range of motion available in the throwing limb typically does not differ from that of the uninvolved limb.^{5,9,32} The total arc of motion has been described by Wilk et al⁴¹ as the full range of motion from maximum external rotation to maximum internal rotation and is reported to be approximately 180°. Thus, for every degree of external rotation gained, a degree of internal rotation can be lost without affecting the function of the throwing shoulder.⁴¹

Range of motion alterations can become problematic in the throwing shoulder when the amount of glenohumeral internal rotation loss exceeds any gain in external rotation.⁴ This condition is a true internal rotation deficit from the total humeral rotation range of motion. The loss of internal rotation is believed to result from contracture and thickening of the posteroinferior portion of the glenohumeral joint capsule, which occurs from the repetitive microtrauma imparted during the deceleration phase of the throwing motion.^{3,31,37} In their review of the disabled throwing shoulder, Burkhart et al³ reported that arthroscopic findings in throwers who exhibit GIRD show a severely contracted and thickened posteroinferior recess in the posterior band of the inferior glenohumeral ligament. Ticker et al³⁶ reported similar results, demonstrating thickened posterior capsules in patients diagnosed with limited internal rotation in conjunction with subacromial impingement. Excessive posterior capsular tightness and GIRD have been implicated in injuries to the throwing shoulder.^{3,37,38,40} Tyler et al³⁸ developed and validated clinical assessment of posterior capsular tightness, which involves measurement of side-lying horizontal adduction of the humerus. It has been acknowledged that the assessment might better represent posterior shoulder tightness rather than isolated capsular tightness, given that other anatomical structures such as the rotator cuff could play a role.²³ Thus, in the current study, we refer to the Tyler et al³⁸ assessment findings as posterior shoulder tightness rather than as posterior capsular tightness. Tyler et al³⁸ demonstrated that throwers have more posterior shoulder tightness than do nonthrowing athletes. In a subsequent study, Tyler et al³⁷ demonstrated that subjects with subacromial impingement develop posterior shoulder tightness.

It has recently been recognized that throwers can feel posterior shoulder pain during the late cocking phase, specifically at end ranges of external rotation.^{15,18,39} Unlike subacromial impingement, classically described by Neer,²⁶ it is believed that this pain results from impingement of the supraspinatus (and occasionally infraspinatus) tendon, between the greater tuberosity and the posterior aspect of the humeral head with the posterosuperior glenoid labrum. Although it is believed that contact between the humeral head and the posterior glenoid rim is a normal physiological occurrence, the biomechanics of the throwing motion is believed to intensify this contact and its effect on the underlying anatomical structures.^{6,8,12,15,19,20,30,39} Thus, pathologic internal impingement can result. Using arthroscopy, clinicians have identified undersurface lesions on the posterior aspect of the supraspinatus tendon and/or anterior portion of the infraspinatus tendon as well as posterosuperior

glenoid labrum fraying (type I or II superior labral anterior posterior [SLAP] lesion) in overhead-throwing athletes.^{6,19,20,39}

In the current study, we believed that posterior shoulder tightness and GIRD may be associated with pathologic internal impingement in throwers. Specifically, we hypothesized that throwers with pathologic internal impingement would exhibit significantly increased posterior shoulder tightness and GIRD without significantly increased external rotation gain. The purpose of this study was to identify increased posterior shoulder tightness and GIRD without increased external rotation gain in throwers diagnosed with pathologic internal impingement.

MATERIALS AND METHODS

Subjects

Eleven male competitive baseball players with diagnosed pathologic internal impingement in the throwing shoulder were matched with 11 control baseball players based on arm dominance, age, height, mass, playing position, and throwing experience. All subjects were between the ages of 18 and 30 years. The group included 14 collegiate baseball players and 8 semiprofessional adult-league participants. Subject demographic characteristics appear in Table 1.

The diagnosis of pathologic internal impingement in the experimental group was made by an orthopaedic surgeon experienced in treating throwing injuries (J.P.B.). A complete history and physical examination were coupled with an MRI arthrogram with gadolinium for diagnosis. Typically, the subjects with pathologic internal impingement demonstrated primary posterior superior shoulder pain that was exacerbated by throwing. The pain specifically intensified in the late-cocking phase of the throwing motion. Additional complaints included decreased ball velocity, endurance, and ball control during throwing. The special tests performed by the orthopaedic surgeon included an apprehension/relocation test, the active compression test of O'Brien et al,²⁸ anterior/posterior drawer test, sulcus test for inferior instability, testing of range of motion, manual muscle testing of strength for the shoulder girdle, and visual appreciation of scapular kinesis. Two of the 11 patients had subtle anterior instability with no frank instability. The MRI arthrogram was read by a board-certified musculoskeletal radiologist, who identified posterior labral fraying (type I or II SLAP lesion) and/or partial undersurface rotator cuff tear at the supraspinatus/infraspinatus junction. All subjects with impingement underwent a course of nonoperative treatment after laboratory tests; those who failed to positively respond to rehabilitation opted for surgical intervention. In the current study, 8 of the 11 subjects who participated eventually underwent surgical intervention, during which the pathologic internal impingement diagnosis was subsequently confirmed.

Other concomitant conditions such as a history of neck pain, external impingement, frank glenohumeral instability, or previous shoulder/elbow injury requiring absence from sport participation (longer than 2 weeks) resulted in exclusion from this study. The control subjects had no significant

TABLE 1
Subject Demographic Characteristics

Variable	Throwers With Impingement (n = 11)	Throwers Without Impingement (n = 11)
Age (mean ± SD), y	22.1 ± 3.5	21.2 ± 1.7
Height (mean ± SD), m	1.8 ± 0.1	1.8 ± 0.1
Mass (mean ± SD), kg	91.0 ± 14.6	89.9 ± 13.0
Throwing experience (mean ± SD), y	16.2 ± 3.5	13.4 ± 2.7
Playing positions	6 pitchers, 3 infielders, 2 outfielders	6 pitchers, 3 infielders, 2 outfielders
Level of skill	7 collegiate, 4 semiprofessional	7 collegiate, 4 semiprofessional

history of shoulder/elbow injury that required absence from participation within the past 2 years.

Procedures

All testing in the current study was performed in a human movement research laboratory at a university-based medical center. Before testing, each subject provided informed consent as required by the university's institutional review board. After consent, bilateral internal and external humeral rotation as well as posterior shoulder tightness were measured by a single examiner. Before the examiner performed this study, test-retest intrasession and intersession reliability as well as precision for the single examiner performing all assessments for range of motion and posterior shoulder tightness were established, yielding intrasession and intraclass correlations^{7,35} ranging from 0.85 to 0.94 and precision (standard error of measurement) of approximately 3° (for range of motion) and 2 cm (for posterior shoulder tightness). Testing of all subjects occurred during their in-season participation.

All range of motion assessments were based on the descriptions of Norkin and White.²⁷ For assessment of external rotation, subjects lay supine on a standard treatment table with their shoulder and elbow in 90° of abduction and flexion, respectively, and the humerus supported by a towel to ensure neutral horizontal positioning (humerus level with acromial process).²⁷ The starting position consisted of placing the forearm approximately perpendicular to the floor so the hand was directed upward toward the ceiling. In this position (0° of rotation), the examiner passively externally rotated the shoulder while stabilizing the scapula (Figure 1A). End range of external rotation was defined as a cease of rotation or when scapular movement was appreciated. At the end range of external rotation, a standard goniometer with a bubble level secured to the stationary arm was positioned with the goniometer axis over the olecranon process and the stationary arm parallel to the floor. The distal arm was then positioned in alignment with the ulnar styloid process. External rotation was the angle created between the stationary and distal goniometer arm. Measurements were taken bilaterally, with 3 measurements taken and averaged for each limb. External rotation gain was calculated as the difference in measured external rotation between the involved (throwing) and uninvolved limb.

Internal rotation was measured using techniques similar to those for external rotation, as previously described.²⁷

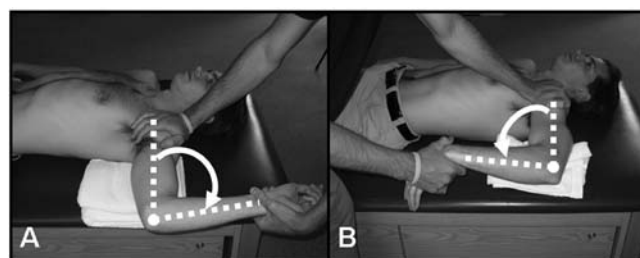


Figure 1. Assessment of glenohumeral external rotation (A) and internal rotation (B).

However, maximum passive internal shoulder rotation was measured (Figure 1B). Glenohumeral internal rotation deficit was calculated as the difference in measured internal rotation between the involved (throwing) and uninvolved limb.

To measure posterior shoulder tightness, a technique described by Tyler et al³⁸ was employed (Figure 2). This technique required the subject to lie on the nontested side, with both the hips and knees in 90° of flexion, the entire body in contact with the table, and the nontesting arm positioned under the subject's head. A small mark was made with a felt-tip pen on the medial epicondyle of the arm to be tested. The subject's acromions were aligned perpendicular to the treatment table with the spine in neutral position. With the tester facing the subject, scapular movement was restricted by stabilizing the lateral border of the scapula in the retracted position and the subject's humerus at 90° of shoulder abduction and 0° of humeral rotation for the beginning of the test. With the subject relaxed, the tester then passively lowered the arm into horizontal adduction while maintaining neutral humeral rotation and scapular stabilization. Full posterior shoulder range of motion was defined as achievement of maximum humeral horizontal adduction or the initiation of scapular motion. At the end range of motion, a second tester recorded the distance (in centimeters) between the felt-tip mark on the medial epicondyle to the bottom of the treatment table surface using a standard tape measure. The amount of horizontal glenohumeral adduction indicated the amount of posterior shoulder tightness; a greater distance between the medial epicondyle and the table indicated increased posterior shoulder tightness. Three measurements were taken bilaterally and averaged for each limb. Posterior shoulder tightness was calculated as the difference in measured horizontal adduction between the involved (throwing) and uninvolved limb.

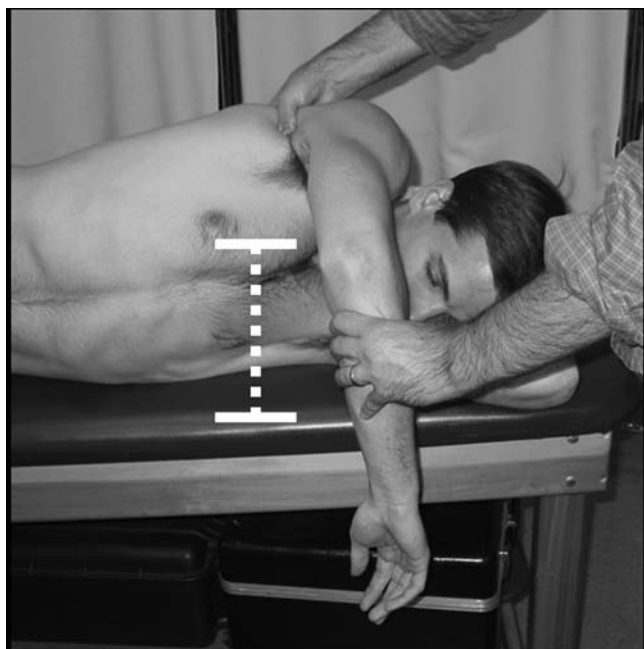


Figure 2. Assessment of posterior shoulder tightness.

Data Reduction and Analysis

The GIRD, external rotation gain, and posterior shoulder tightness variables used for statistical analysis were calculated as the difference in amount of internal rotation, external rotation, and horizontal adduction, respectively, between the involved (throwing) and uninvolved (nonthrowing) limb. A 2-tailed, dependent-sample *t* test (SPSS version 11.0, SPSS Inc, Chicago Ill) was used to compare group differences for GIRD, external rotation gain, and posterior shoulder tightness. This statistical procedure was chosen because the variables (GIRD, external rotation gain, and posterior shoulder tightness) used for analysis take into account side-to-side differences. This approach was employed rather than a 2-factor (group and limb) analysis of variance model to reduce the variability in the amount of range of motion and tightness that might exist between subjects. An α level of .05 was set prior to all analyses.

RESULTS

The descriptive statistics for the internal rotation, the external rotation, and the posterior shoulder tightness of both involved and uninvolved limbs as well as the GIRD, external rotation gain, and difference in posterior shoulder tightness for the 2 groups appear in Table 2. The throwing athletes with pathologic internal impingement demonstrated significantly greater GIRD (impingement group = -19.7° , controls = -11.1° ; $t_{20} = -2.14$, $P = .03$) (Figure 3) and significantly greater posterior shoulder tightness (impingement group = -4.2 cm, controls = -0.9 cm; $t_{20} = -2.72$, $P = .03$) (Figure 4) compared with the control subjects. No significant differences were observed in external rotation gain between

the 2 groups (impingement group = 8.3° , controls = 5.1° ; $t_{20} = 1.59$, $P = .16$) (Figure 3).

DISCUSSION

Glenohumeral internal rotation deficits and posterior shoulder tightness are common traits found in the throwing arm of all throwers.^{1,2,5,9,32,34,38} Yet these results demonstrate that throwers with pathologic internal impingement are unique in that they have significantly increased posterior shoulder tightness and GIRD compared with normal throwers. In addition, the throwing athletes with pathologic internal impingement did not demonstrate the significant increase in external rotation gain that typically accompanies losses in internal rotation found in the normal, healthy throwing shoulder.

A review of the literature indicates that the amount of GIRD typically present in throwers without a history of shoulder injury is in the range of 10° to 15° ,^{2,5,32,38} comparing favorably with the results from the throwers without impingement in the current study (11.1°). The throwers with pathologic internal impingement had significantly increased GIRD (19.7°). Comparing our results with other research findings is difficult, given that there are little published data on GIRD in throwers with shoulder injury and no research related to pathologic internal impingement. Tyler et al³⁷ demonstrated a loss of almost 22° of internal rotation motion in patients (nonthrowers) with subacromial impingement. Warner et al⁴⁰ reported similar decrements associated with impingement. Burkhart et al³ reported unpublished data in which GIRD in excess of 25° was present in throwers with diagnosed type II SLAP lesions. Similar amounts of GIRD were found in the subjects with pathologic internal impingement who participated in the current study.

The throwers with pathologic internal impingement in the current study exhibited posterior shoulder tightness as measured with cross-body horizontal adduction. Both Tyler et al³⁷ and Warner et al⁴⁰ reported similar levels of posterior shoulder tightness (approximately 4-6 cm) in nonthrowing patients with subacromial impingement and suggested that posterior capsular contracture was the cause of the shoulder tightness. Again, no research to date describes the amount of posterior shoulder tightness present in throwers with pathologic internal impingement. Tyler et al³⁷ reported that posterior shoulder tightness (as measured with cross-body horizontal adduction) and internal rotation are interrelated. It was reported that for every 4° of GIRD, a 1-cm increase in distance between the medial epicondyle and treatment table will be present, indicating increased posterior shoulder tightness. The average loss of internal rotation in the subjects with pathologic internal impingement in this study was 19.7° , whereas the average change in posterior capsule tightness was 4.2 cm. This finding equates to approximately 4.7° of loss of internal rotation for every 1-cm change in posterior shoulder tightness, comparing favorably with the Tyler et al³⁷ dataset. The GIRD and posterior shoulder tightness identified with the Tyler et al³⁷ method in the current study might be indicative of adaptive changes to the posterior shoulder structures, including the

TABLE 2
Glenohumeral Rotation and Posterior Shoulder Tightness Variables Assessed^a

Variable	Throwers With Impingement	Throwers Without Impingement	P
Internal rotation, deg			
Involved limb	42.5 ± 12.1	51.1 ± 14.4	
Uninvolved limb	62.2 ± 16.9	62.2 ± 13.7	
GIRD, deg	-19.7 ± 12.8	-11.1 ± 9.4	.03 ^b
External rotation, deg			
Involved limb	125.8 ± 13.1	121.1 ± 8.7	
Uninvolved limb	117.5 ± 16.7	116.0 ± 10.3	
ERG, deg	8.3 ± 9.2	5.1 ± 5.3	.16
Posterior shoulder tightness, cm			
Involved limb	27.0 ± 5.9	21.1 ± 6.2	
Uninvolved limb	22.8 ± 4.3	21.9 ± 5.9	
ΔPST, cm	-4.2 ± 4.4	-0.9 ± 2.0	.03 ^b

^aValues are given as means ± SDs. GIRD, glenohumeral internal rotation deficit; ERG, external rotation gain; ΔPST, difference in posterior shoulder tightness.

^bSignificant difference between groups (*P* < .05).

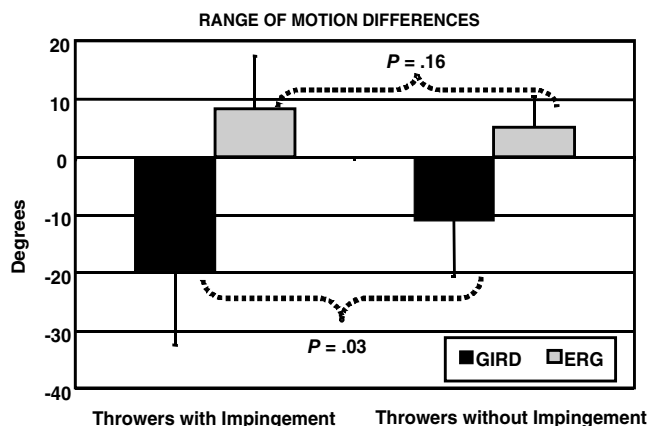


Figure 3. Glenohumeral internal rotation deficit (GIRD) and external rotation gain (ERG) in throwers with and without pathologic internal impingement.

capsular and rotator cuff musculature, in the throwers with pathologic internal impingement.

Pathomechanically, posterior shoulder tightness likely contributes to pathologic internal impingement. Harryman et al¹³ demonstrated that when asymmetric tension within the capsule is present, alterations in the arthrokinematics of the glenohumeral joint result. For example, tightness in the posteroinferior capsule results in anterosuperior migration of the humeral head on the glenoid.¹³ This migration can contribute to impingement of the posterior cuff tendons. In addition, some posterior translation is necessary when the shoulder is in a position of abduction with external humeral rotation (ie, the late cocking phase).²¹ This posterior translation is limited when posterior capsular tightness is present. Burkhart et al³ and Morgan and associates²⁴ suggest in their reviews that the primary “culprit” to shoulder injury in throwers is posterior capsule contracture. They proposed that posterior capsular contracture shifts the glenohumeral fulcrum posterosuperiorly. As the shoulder externally rotates around the new fulcrum point,

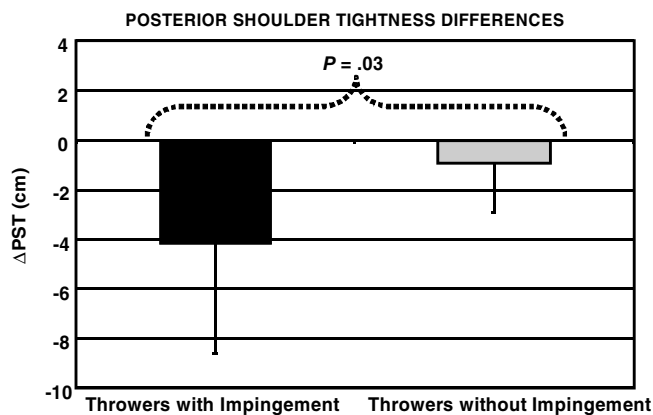


Figure 4. Posterior shoulder tightness (PST) in throwers with and without pathologic internal impingement. ΔPST, difference in posterior shoulder tightness.

there is increased contact of the rotator cuff and posterior labrum.¹⁴ Grossman et al¹¹ used a cadaveric model to demonstrate that posterior capsular contracture with decreased internal rotation does not allow the humerus to externally rotate into its normal posteroinferior position in the cocking phase of throwing. The result might be impingement of the rotator cuff in the posterior shoulder. This impingement might be compounded if the scapula is in a more protracted position. Recently, Myers et al²⁵ demonstrated that throwers with pathologic internal impingement exhibit a more protracted scapula, possibly compounding the impingement.

Given the presence of posterior shoulder tightness and loss of glenohumeral internal rotation in throwers with pathologic internal impingement, some authors advocate stretching for restoration of posterior shoulder flexibility.^{14,22,41} Kibler and Chandler¹⁷ have described and validated an injury risk modification program for overhead-throwing athletes resulting in improved range of motion in the upper extremity. In a separate study, Kibler¹⁶

also demonstrated that daily posteroinferior capsular stretching in a group of tennis players resulted in decreased GIRD and decreased incidence of injury compared with a control group. Burkhart et al³ reported that manual stretching to minimize GIRD in a group of major league pitchers resulted in decreased injury. They believed that 90% of all throwers with symptomatic GIRD and posterior shoulder tightness will respond positively to a posteroinferior capsular stretching program. On the basis of the published literature, the posterior shoulder tightness and GIRD identified in the throwers of the current study may respond favorably to a stretching program targeting the posterior structures.

There are several limitations that warrant acknowledgment. In this study, the group of throwers was composed of both pitchers and position players (ie, infielders and outfielders). There are data to suggest that differences in range of motion exist between these 2 groups, with pitchers exhibiting more external rotation and less internal rotation compared with position players.² We employed a matched-control group design to control for these inherent differences. Thus, each subject with diagnosed impingement was matched with a control subject who played the same position. We also did not examine the amount of humeral retroversion present in the throwing participants. Thus, we cannot comment on if and how much of the range of motion differences found in this study might have resulted from possible humeral version differences. It was our hope that by matching our subjects by years of participation, we could control this confounding variable. Fully understanding the influence of humeral retroversion on pathologic internal impingement is an area of future research. An additional limitation that warrants discussion is the assessment used to measure posterior shoulder tightness. Although it was meant to be an indicator of posterior capsular tightness, we, as well as others,²³ recognize that assessment of internal rotation range of motion and cross-body glenohumeral horizontal adduction does not isolate the posterior capsule and may be influenced by the posterior rotator cuff musculature. Currently, there are no in vivo means of assessing posterior capsular tightness and isolating the posterior capsule. Thus, we opted for the 2 assessments (cross-body horizontal adduction and glenohumeral internal rotation) that were found to be reliable and used most often by clinicians.

CONCLUSION

Throwing athletes with pathologic internal impingement demonstrated significantly greater glenohumeral internal rotation deficits and posterior shoulder tightness compared to control subjects in this study. In addition, no significant differences were observed in external rotation gain in throwers with pathologic internal impingement. These findings could indicate a tightening of the posterior shoulder elements (capsule, rotator cuff), which may contribute to impingement. The results suggest that injury management should include stretching to restore flexibility to the posterior shoulder.

ACKNOWLEDGMENT

This study was funded by the National Football League Charities.

REFERENCES

1. Bigliani LU, Codd TP, Connor PM, Levine WN, Littlefield MA, Hershon SJ. Shoulder motion and laxity in the professional baseball player. *Am J Sports Med.* 1997;25:609-613.
2. Brown LP, Niehues SL, Harrah A, Yavorsky P, Hirshman HP. Upper extremity range of motion and isokinetic strength of the internal and external shoulder rotators in major league baseball players. *Am J Sports Med.* 1988;16:577-585.
3. Burkhart SS, Morgan CD, Kibler WB. The disabled throwing shoulder: spectrum of pathology. Part I: pathoanatomy and biomechanics. *Arthroscopy.* 2003;19:404-420.
4. Burkhart SS, Morgan CD, Kibler WB. The disabled throwing shoulder: spectrum of pathology. Part III: the SICK scapula, scapular dyskinesis, the kinetic chain, and rehabilitation. *Arthroscopy.* 2003;19:641-661.
5. Crockett HC, Gross LB, Wilk KE, et al. Osseous adaptation and range of motion at the glenohumeral joint in professional baseball pitchers. *Am J Sports Med.* 2002;30:20-26.
6. Davidson PA, Elattrache NS, Jobe CM, Jobe FW. Rotator cuff and posterior-superior glenoid labrum injury associated with increased glenohumeral motion: a new site of impingement. *J Shoulder Elbow Surg.* 1995;4:384-390.
7. Denegar CR, Ball DW. Assessing reliability and precision of measurement: an introduction to intraclass correlation and standard error of measurement. *J Sport Rehabil.* 1993;2:35-42.
8. Edelson G, Teitz C. Internal impingement in the shoulder. *J Shoulder Elbow Surg.* 2000;9:308-315.
9. Ellenbecker TS, Roetert EP, Baillie DS, Davies GJ, Brown SW. Glenohumeral joint total rotation range of motion in elite tennis players and baseball pitchers. *Med Sci Sports Exerc.* 2002;34:2052-2056.
10. Garth WP Jr, Allman FL Jr, Armstrong WS. Occult anterior subluxations of the shoulder in noncontact sports. *Am J Sports Med.* 1987;15:579-585.
11. Grossman MG, Tibone JE, McGarry MH, Schneider DJ, Veneziani S, Lee TQ. A cadaveric model of the throwing shoulder: a possible etiology of superior labrum anterior-to-posterior lesions. *J Bone Joint Surg Am.* 2005;87:824-831.
12. Halbrecht JL, Tirman P, Atkin D. Internal impingement of the shoulder: comparison of findings between the throwing and nonthrowing shoulders of college baseball players. *Arthroscopy.* 1999;15:253-258.
13. Harryman DT, Sidles JA, Clark JM, McQuade KJ, Gibb TD, Matsen FA III. Translation of the humeral head on the glenoid with passive glenohumeral motion. *J Bone Joint Surg Am.* 1990;72:1334-1343.
14. Jazrawi LM, McCluskey GM III, Andrews JR. Superior labral anterior and posterior lesions and internal impingement in the overhead athlete. *Instr Course Lect.* 2003;52:43-63.
15. Jobe CM. Posterior glenoid impingement. *Arthroscopy.* 1995;11:530-536.
16. Kibler WB. The relationship of glenohumeral internal rotation deficit to shoulder and elbow injuries in tennis players: a prospective evaluation of posterior capsular stretching. Paper presented at: American Shoulder and Elbow Surgeons 15th Annual Closed Meeting; November 6, 1998; New York, NY.
17. Kibler WB, Chandler TJ. Range of motion in junior tennis players participating in an injury risk modification program. *J Sci Med Sport.* 2003;6:51-62.
18. Kvitne RS, Jobe FW. The diagnosis and treatment of anterior instability in the throwing athlete. *Clin Orthop Relat Res.* 1993;291:107-123.
19. Liu SH, Boynton E. Posterior superior impingement of the rotator cuff on the glenoid rim as a cause of shoulder pain in the overhead athlete. *Arthroscopy.* 1993;9:697-699.

20. McFarland EG, Hsu CY, Neira C, O'Neil O. Internal impingement of the shoulder: a clinical and arthroscopic analysis. *J Shoulder Elbow Surg.* 1999;8:458-460.
21. Meister K. Injuries to the shoulder in the throwing athlete. Part one: Biomechanics/pathophysiology/classification of injury. *Am J Sports Med.* 2000;28:265-275.
22. Meister K. Injuries to the shoulder in the throwing athlete. Part two: evaluation/treatment. *Am J Sports Med.* 2000;28:587-601.
23. Michener LA, McClure PW, Karduna AR. Anatomical and biomechanical mechanisms of subacromial impingement syndrome. *Clin Biomech (Bristol, Avon).* 2003;18:369-379.
24. Morgan CD, Burkhart SS, Palmeri M, Gillespie M. Type II SLAP lesions: three subtypes and their relationships to superior instability and rotator cuff tears. *Arthroscopy.* 1998;14:553-565.
25. Myers JB, Laudner KG, Pasquale MR, et al. Scapular dysfunction in throwers with posterior internal impingement. Paper presented at: Orthopaedic Research Society 51st Annual Meeting; February 20-23, 2005; Washington, DC.
26. Neer CS II. Impingement lesions. *Clin Orthop Relat Res.* 1983;173:70-77.
27. Norkin CC, White DJ. *Measurement of Joint Motion: A Guide to Geometry.* 3rd ed. Philadelphia, Pa: FA Davis Company; 2003.
28. O'Brien SJ, Allen AA, Coleman SH, Drakos MC. The trans-rotator cuff approach to SLAP lesions: technical aspects for repair and a clinical follow-up of 31 patients at a minimum of 2 years. *Arthroscopy.* 2002;18:372-377.
29. Osbahr DC, Cannon DL, Speer KP. Retroversion of the humerus in the throwing shoulder of college baseball pitchers. *Am J Sports Med.* 2002;30:347-353.
30. Paley KJ, Jobe FW, Pink MM, Kvitne RS, ElAttrache NS. Arthroscopic findings in the overhand throwing athlete: evidence for posterior internal impingement of the rotator cuff. *Arthroscopy.* 2000;16:35-40.
31. Pappas AM, Zawacki RM, McCarthy CF. Rehabilitation of the pitching shoulder. *Am J Sports Med.* 1985;13:223-235.
32. Reagan KM, Meister K, Horodyski MB, Werner DW, Carruthers C, Wilk K. Humeral retroversion and its relationship to glenohumeral rotation in the shoulder of college baseball players. *Am J Sports Med.* 2002;30:354-360.
33. Rubenstein DL, Jobe FW, Glousman RE, et al. Anterior capsulolabral reconstruction of the shoulder in athletes. *J Shoulder Elbow Surg.* 1992;1:229-237.
34. Safran MR, Borsa PA, Lephart SM, Fu FH, Warner JJ. Shoulder proprioception in baseball pitchers. *J Shoulder Elbow Surg.* 2001;10:438-444.
35. Shrout PE, Fleiss JL. Intraclass correlations: uses in assessing rater reliability. *Psychol Bull.* 1979;86:420-428.
36. Ticker JB, Beim GM, Warner JJ. Recognition and treatment of refractory posterior capsular contracture of the shoulder. *Arthroscopy.* 2000;16:27-34.
37. Tyler TF, Nicholas SJ, Roy T, Gleim GW. Quantification of posterior capsule tightness and motion loss in patients with shoulder impingement. *Am J Sports Med.* 2000;28:668-673.
38. Tyler TF, Roy T, Nicholas SJ, Gleim GW. Reliability and validity of a new method of measuring posterior shoulder tightness. *J Orthop Sports Phys Ther.* 1999;29:262-269, discussion 270-274.
39. Walch G, Boileau P, Noel E, et al. Impingement of the deep surface of the supraspinatus tendon on the posterosuperior glenoid rim: an arthroscopic study. *J Shoulder Elbow Surg.* 1992;1:238-245.
40. Warner JJ, Micheli LJ, Arslanian LE, Kennedy J, Kennedy R. Patterns of flexibility, laxity, and strength in normal shoulders and shoulders with instability and impingement. *Am J Sports Med.* 1990;18:366-375.
41. Wilk KE, Meister K, Andrews JR. Current concepts in the rehabilitation of the overhead throwing athlete. *Am J Sports Med.* 2002;30:136-151.